



The Smart Dentin Grinder

CASE STUDIES



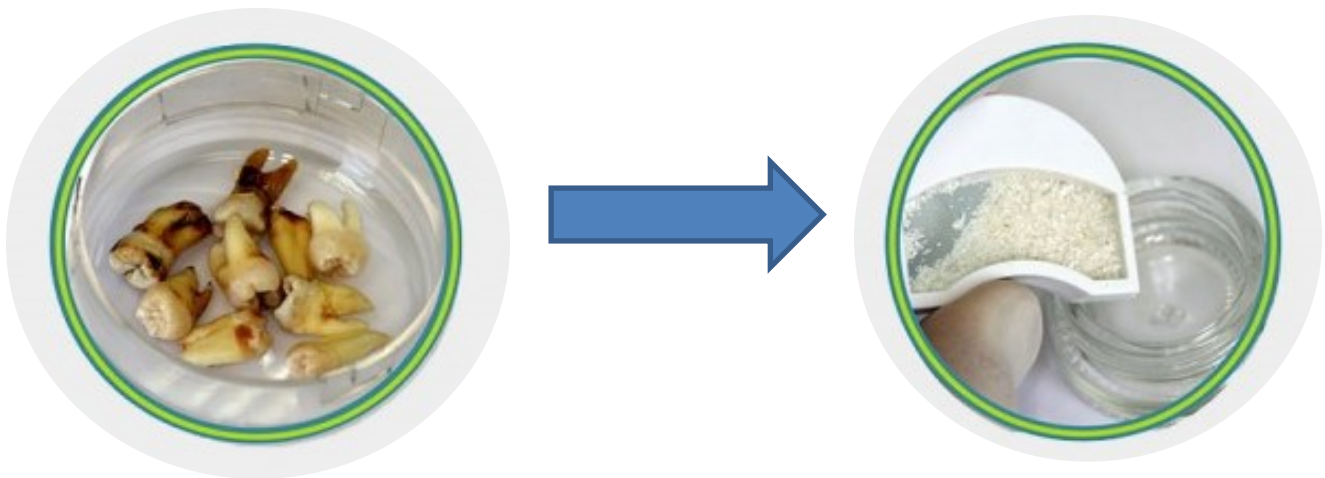
*Don't Throw Away Good Teeth –
Teeth Generate Bone*

www.kometabio.com

info@kometabio.com

***Don't throw away
extracted teeth.***

**Use them as the best
quality autologous graft,
to provide superior
aesthetic results for
your patient.**



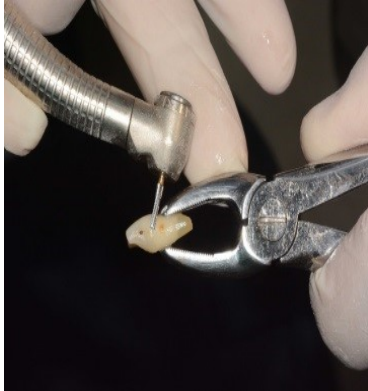Introduction

The Smart Dentin Grinder offers a simple and efficient way to use autogenic qualities to provide superior aesthetic care.

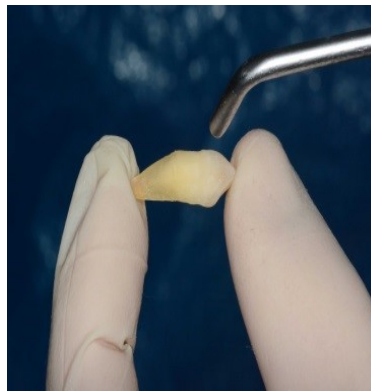
These include:

- Ankylosis – natural fusion of autogenic graft with site bone which accelerates healing*
- Rapid restoration due to fast osteo-integration*
- Osteogenic and osteoconductive properties*
- Maintain bone level with minimal graft resorption*
- No disease transmission or allograft related complications*
- More economical than most grafts on the market*
- Bone replacement remodeling over time*

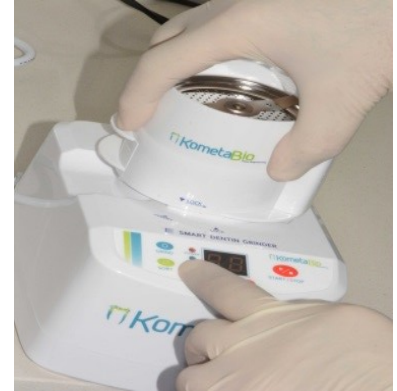The Protocol



Clean debris



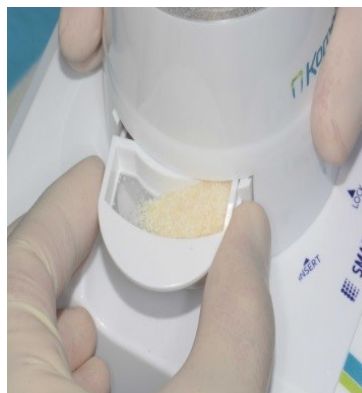Dry tooth



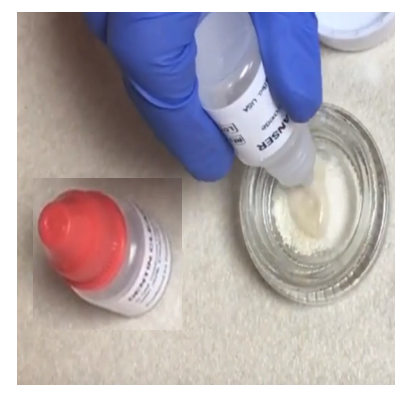Place in chamber



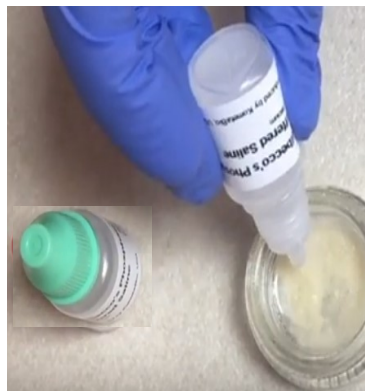
Grind & sort



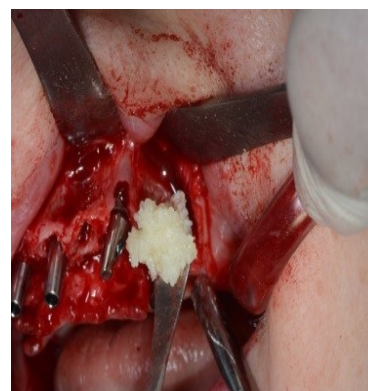
Extract graft



Apply Dentin
Cleanser



Apply PBS Wash



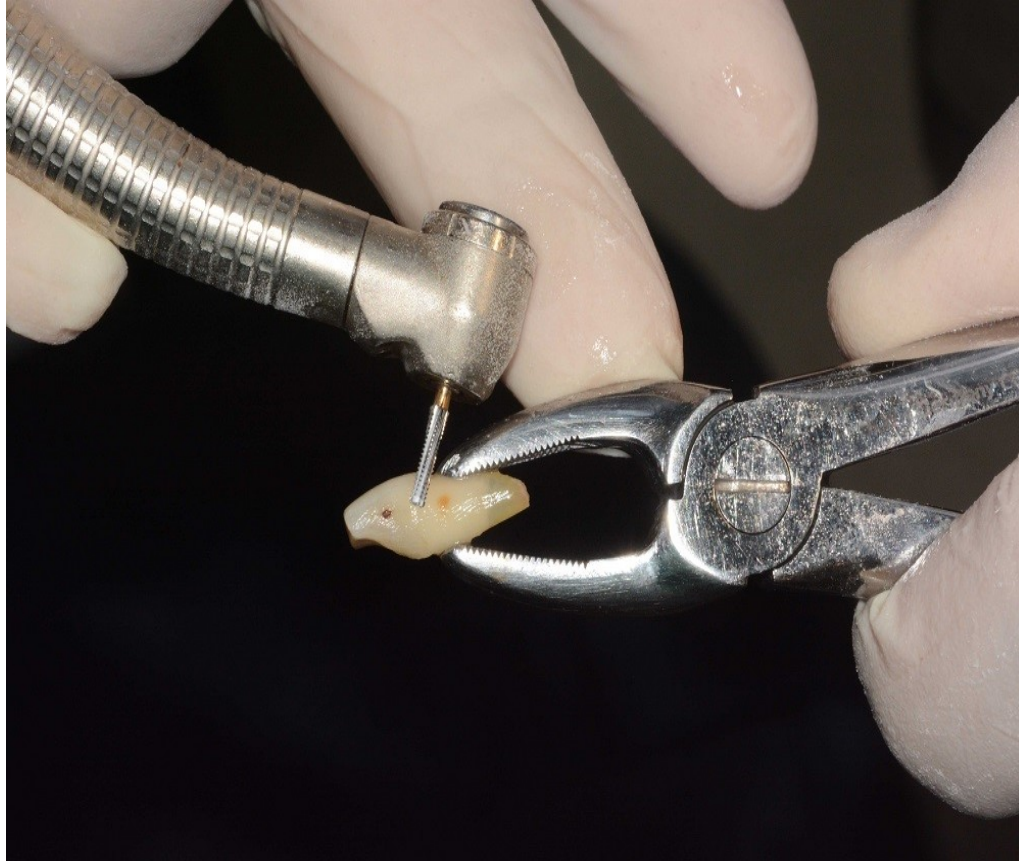
Place graft

Clean debris



Min.

8
7
6
5
4
3
2
1

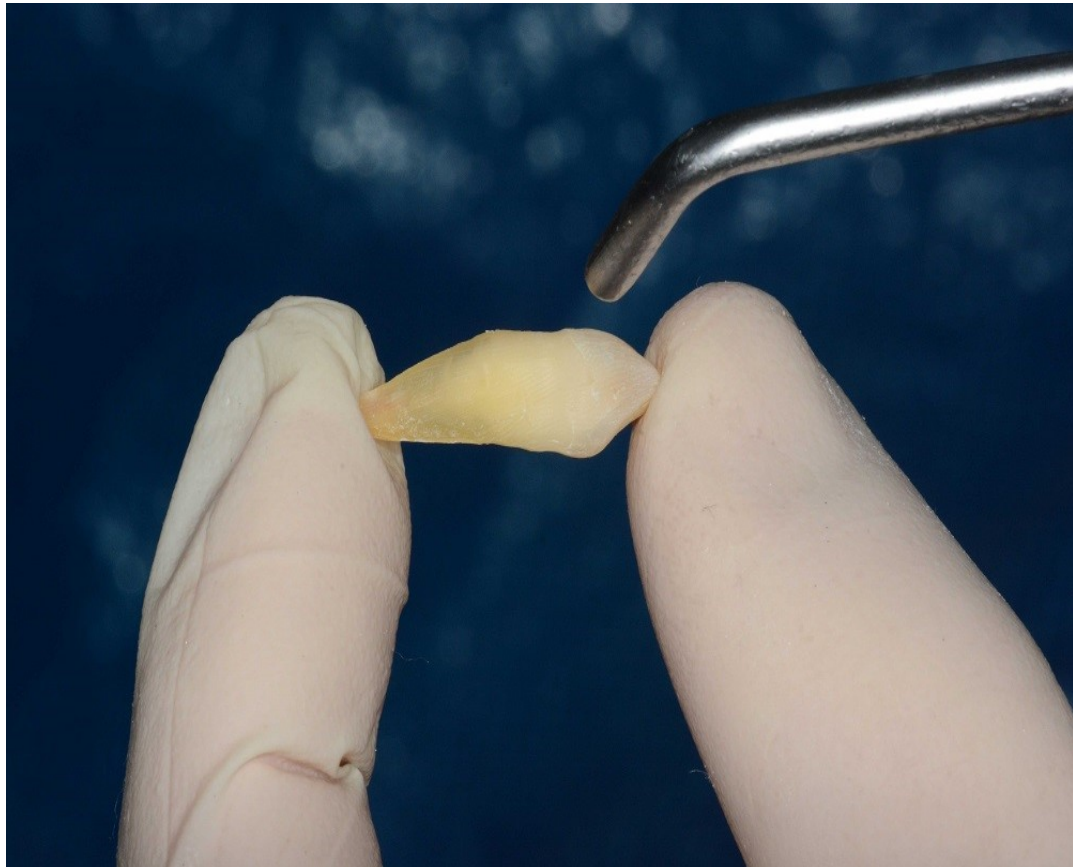
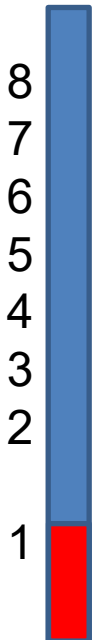


Use a tungsten bur to remove all cavities, artificial material and debris from the extracted teeth, so that only the clean tooth remains.

Dry tooth



Min.

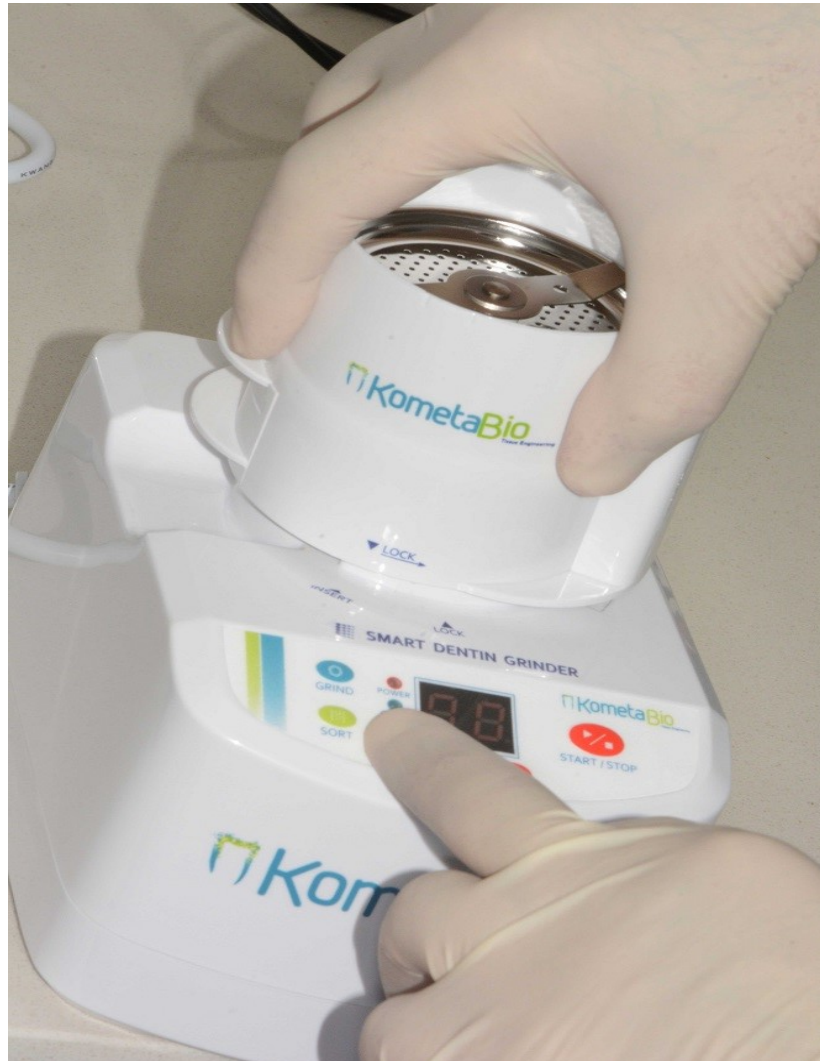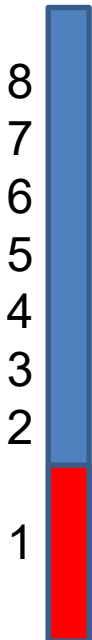


Dry the teeth well by air syringe. This will drastically reduce the amount of graft that will be lost during the grinding and sorting process.

Place grinding chamber

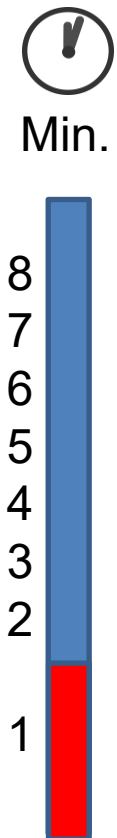


Min.



Place the chamber on the top of the Smart Dentin Grinder. Align the small arrow on the chamber with the one in the center of the grinder. Turn the chamber counterclockwise to lock it in position. When locked, the **LOCK** indicator arrow on the chamber is to the right of the arrow in the center of the grinder.

Grind and sort

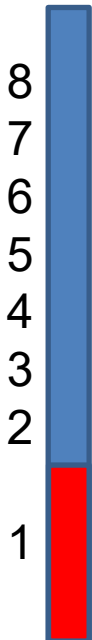


Switch on the Smart Dentin Grinder. Place the prepared teeth on the grinding sieve next to the blades. Close the chamber cap and twist it counterclockwise so that it clicks into place. Press the **GRIND** button. The **GRIND** indicator lights up. Press the **UP** and/or the **DOWN** button as many times as needed in order to set the preferred Grinding Time. We strongly recommend setting grinding time to **3 seconds**. Press the **SORT** button. The **SORT** indicator lights up. Press the **UP** and/or the **DOWN** button as many times as needed in order to set the preferred Sorting Time. We recommend setting sorting time to **20 seconds**. Press the **START** button to start the grinding process. If large pieces are left in the grinding chamber, press the **START** button again to grind for another 3 seconds and to sort for another 20 seconds. Be sure that no dentin particles are left in the grinding chamber.

Extract graft



Min.

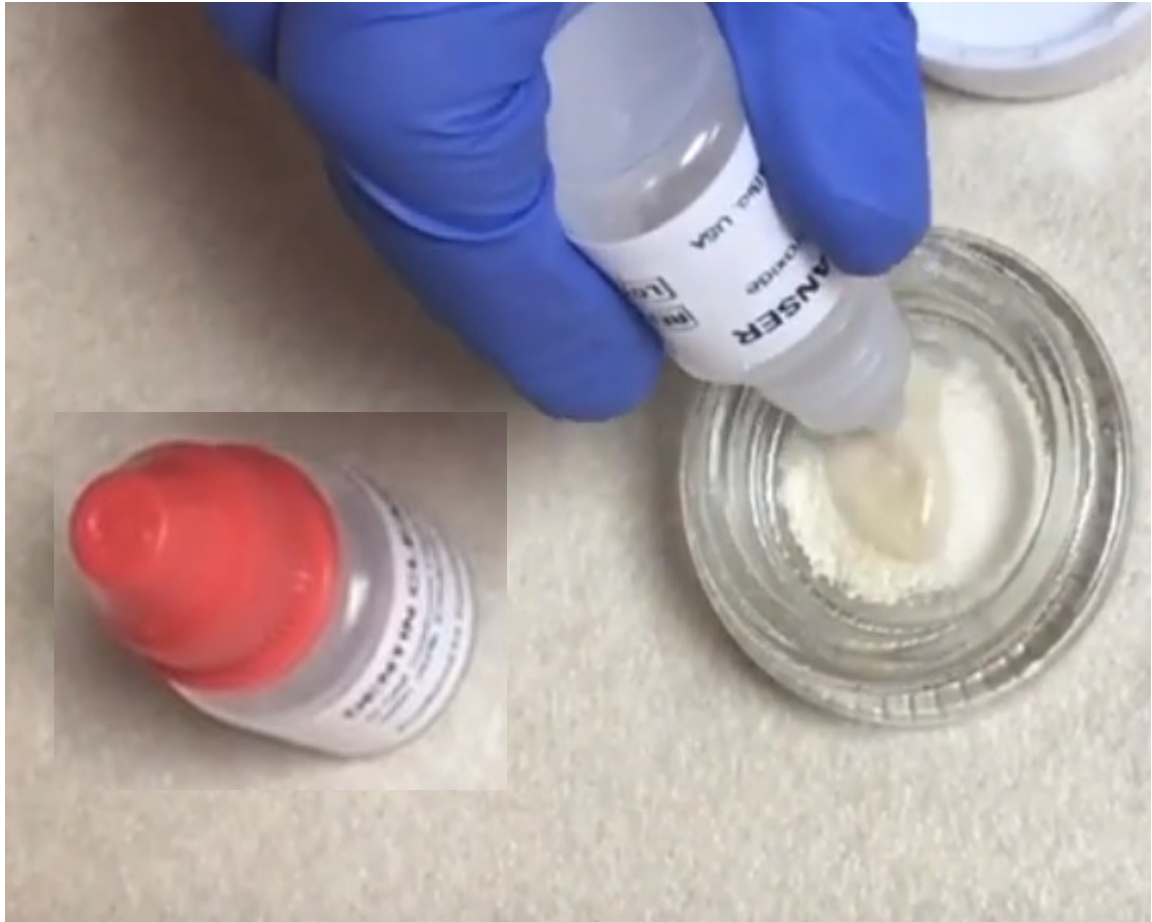


Pull out/apart the top drawer compartment, which contains particles of between 300 – 1,200 microns. If you feel that’s not enough graft, you can always add the granules from the lower compartment which are smaller than 300 microns but can certainly be used in conjunction with the larger particulate.

Apply Dentin Cleaser



Min.

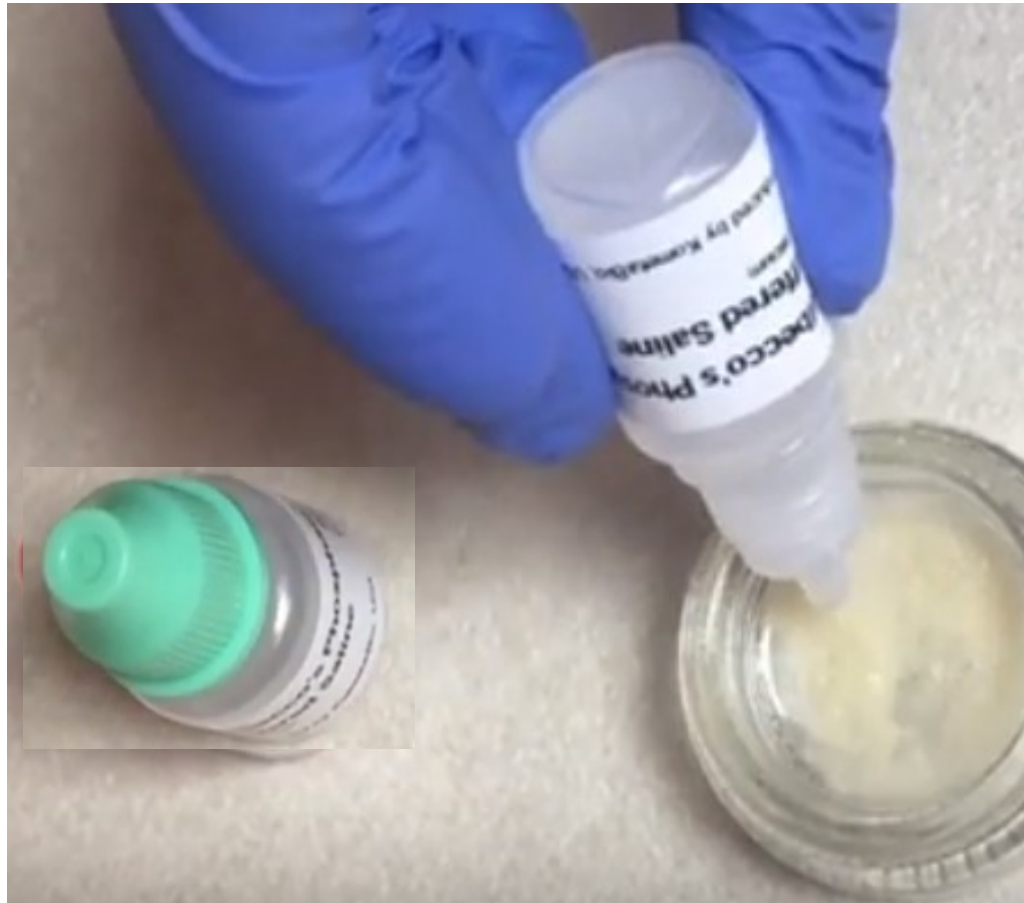


Pour the contents of the top drawer compartment into one of the provided containers (Dappen dish). Pour the provided Dentin Cleanser (RED CAP bottle) into the container with the particulate. Fill to cover the particulate. Close the container's cap by turning it clockwise. Leave the particulate in the cleansing solution for 5 minutes at room temperature. Using a cotton gauze, absorb the cleansing solution.

Apply PBS Wash



Min.

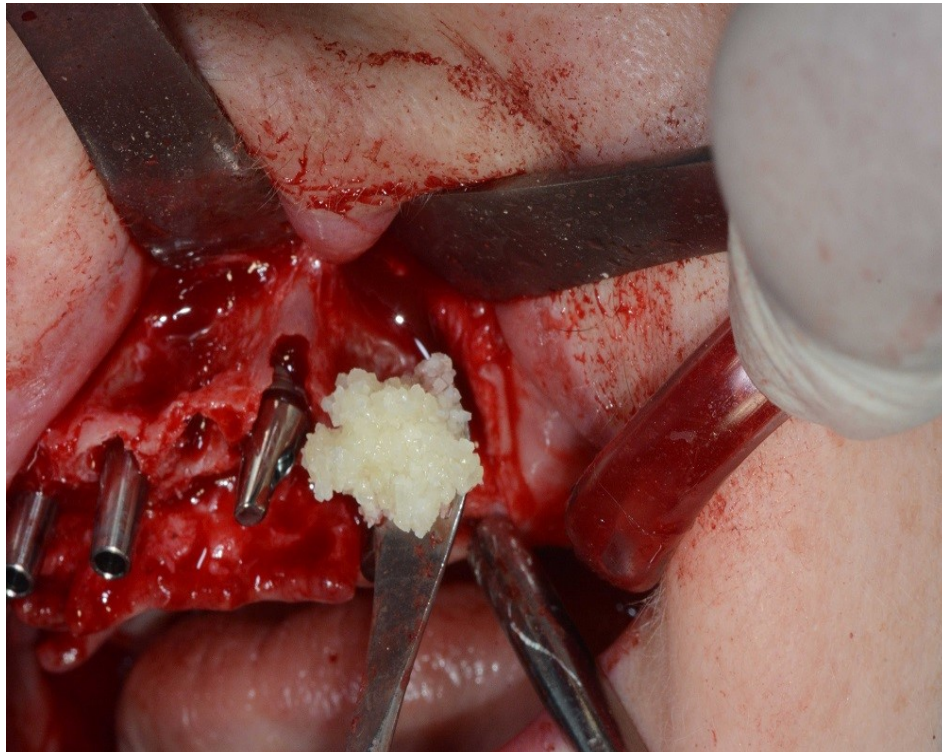


Pour Phosphate Buffered Saline (PBS), GREEN CAP bottle, into the container. Fill approximately half the container. Stir the container gently or use a spatula to mix. Using a cotton gauze, absorb the excess PBS solution. Repeat this process a second time. After the second time the particulate dentin is ready for immediate grafting.

Place graft



Min.



Place the wet dentin graft in the site and use it exactly the same way you would use any other type of graft.

Cases, Indications and Findings

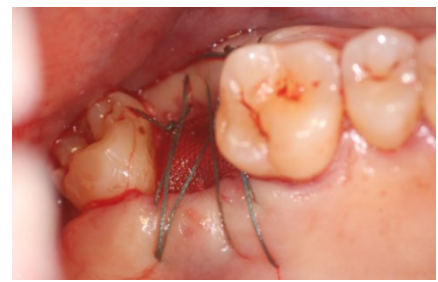
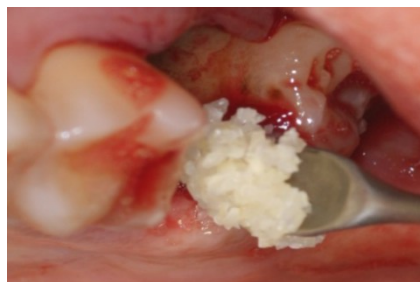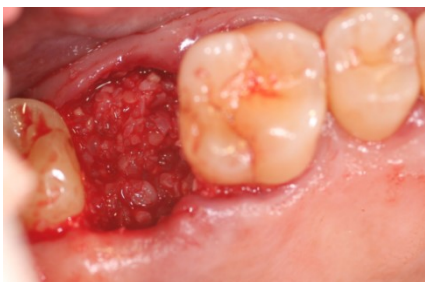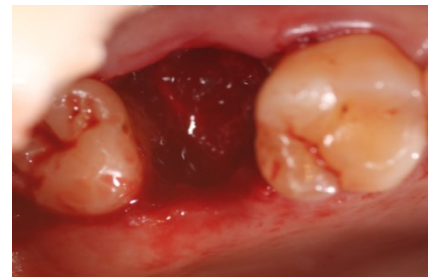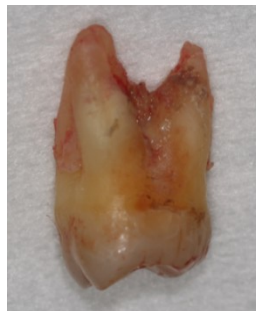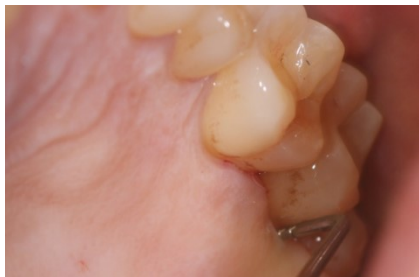A classic socket preservation with best ridge maintenance

Case description: Deep intrabony pockets of tooth # 27, high mobility and pain.

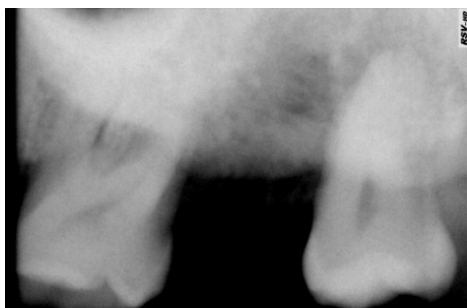
Decision: To extract this tooth in order to prevent spread of infection to neighboring teeth.

Procedure: A periodontal involved 2nd upper molar was extracted. The tooth was cleaned and dried. Grinding and cleansing was performed and 15 minutes after extraction the dentin graft was ready for use. During the cleanser process, a membrane was prepared to cover the socket. Use of membrane was selected since dentist was unable to cover the grafted socket by soft tissue.

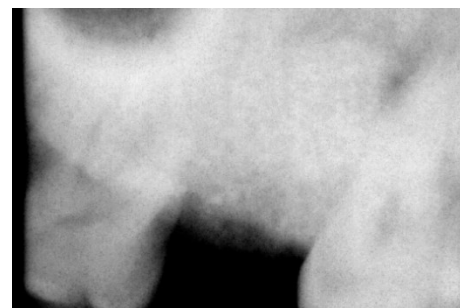
Result: In the 4 month x-ray, high density bone and no reduction of dentin-bone level was observed.



Bacteria free clean dentin particulates grafted into fresh extraction site



At time of extraction



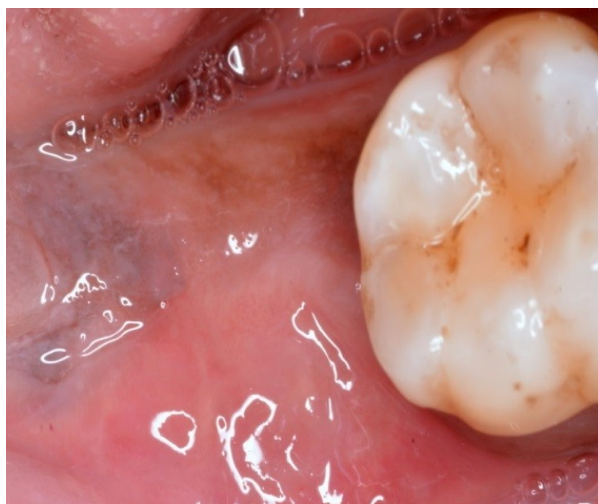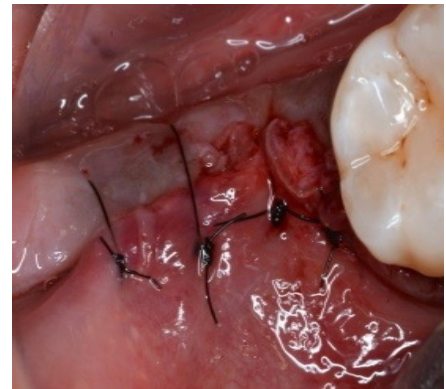
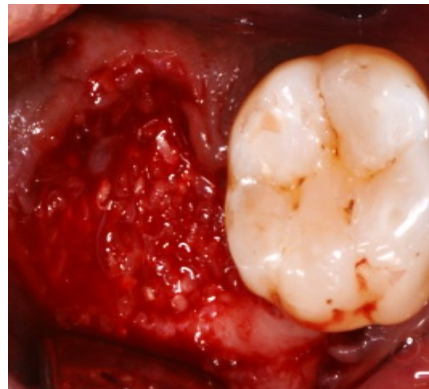
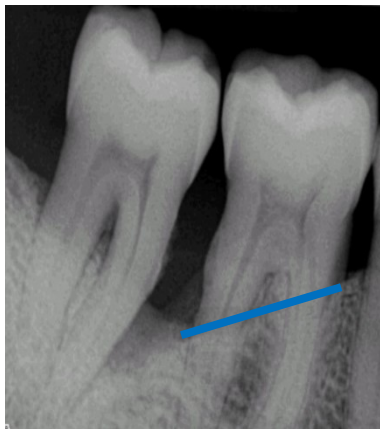4 months after grafting

The case was presented by Dr. Estrade and Dr. Metivier in Dental Tribune, 2015.

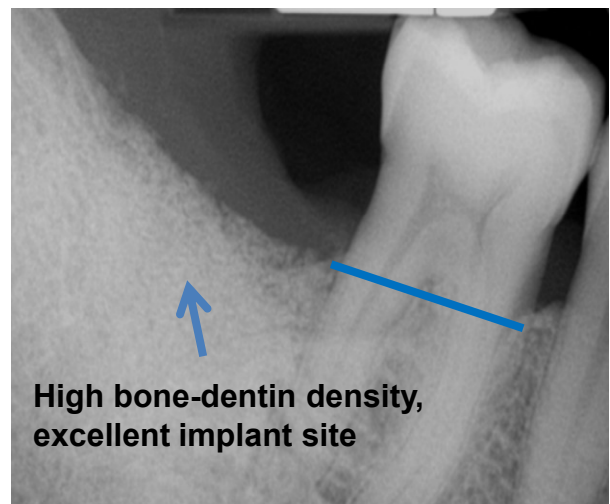
Saving the proximal tooth by augmenting alveolar ridge

Case description: Deep intrabony pocket defect and bifurcation involved tooth #37. Tooth was extracted. Roots ground and grafted. See bone level one month later.

Results: Tooth #36 was preserved and supported due to an effective autologous grafting procedure. **AUTOLOGOUS DENTIN GRAFT OF EXTRACTED TOOTH IMPROVES SIGNIFICANTLY BONE LEVEL OF THE PROXIMAL TOOTH**



2 weeks after grafting

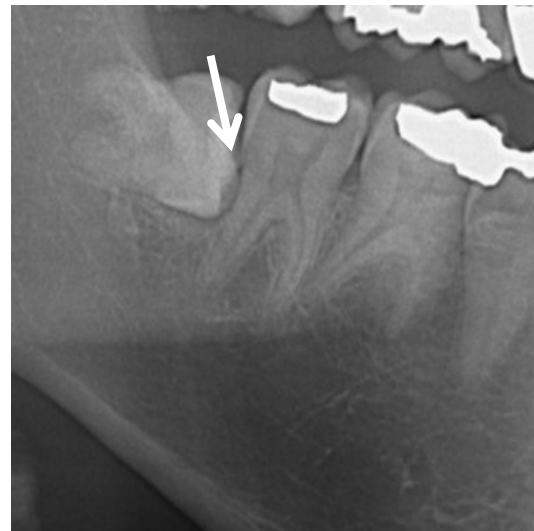
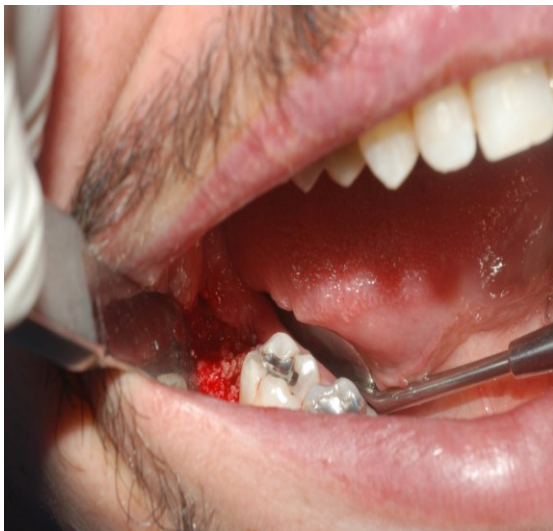
1 month after grafting

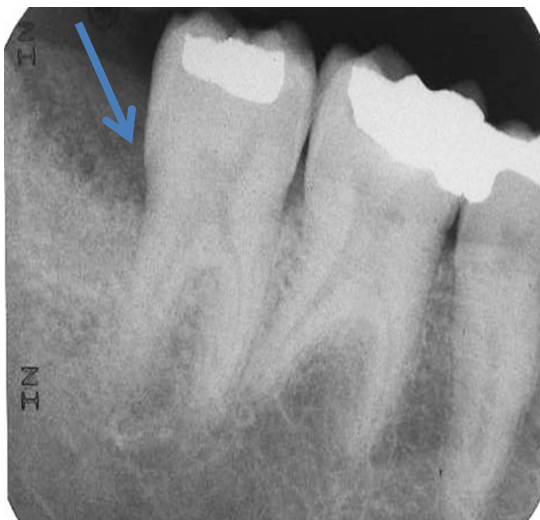Grafting of bone defect after extraction of impacted tooth

Case description: Male 27y old. Horizontal #38 tooth impaction. Surgical extraction resulted in deep bone crater and exposed surface of distal root of tooth #37. Augmentation of bone defect and intrabony pocket of distal root #37 (see arrow).

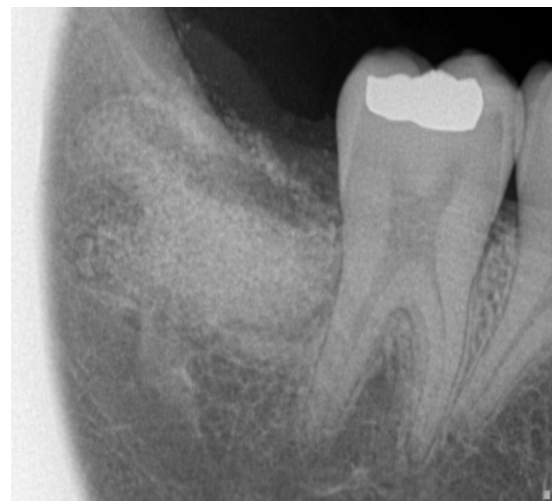Results: Prevented tooth loss of #37. GRAFTING OF AUTOLOGOUS DENTIN REGENERATES NORMAL BONE ANATOMY AND SUPPORTS TOOTH #37.



Day of surgery



After 3 month

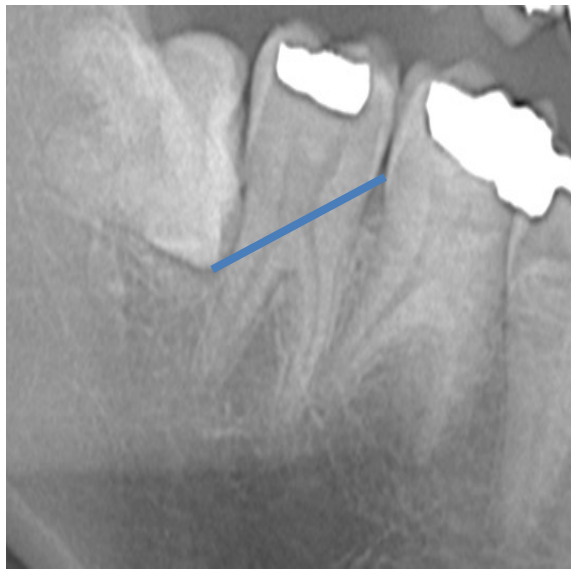

At surgery

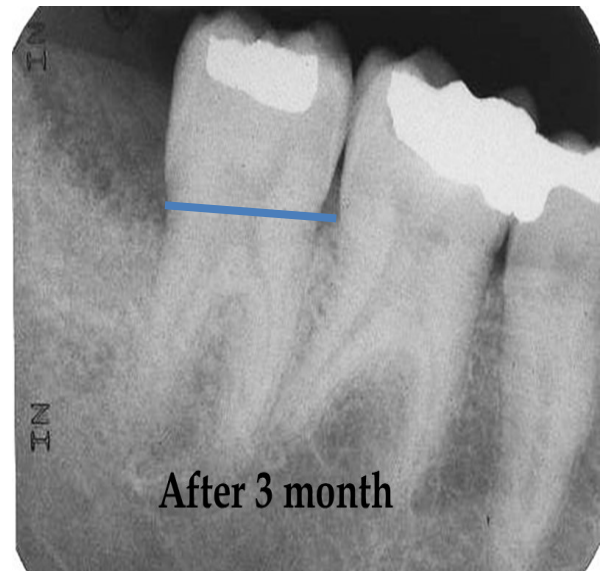Bone management: Two comparative cases

The following two cases present bone management using autologous dentin graft. These two cases show how effective dentin graft is to build up bone mass rapidly as well as maintain bone level over time. In these specific cases the graft is used in order to support the distal root.

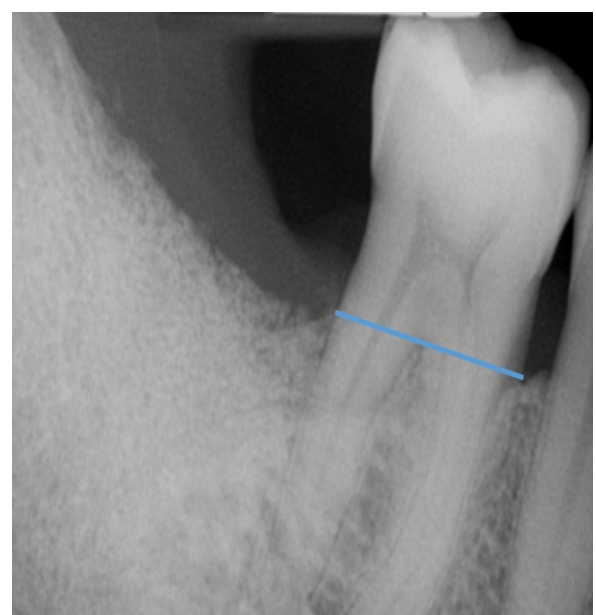
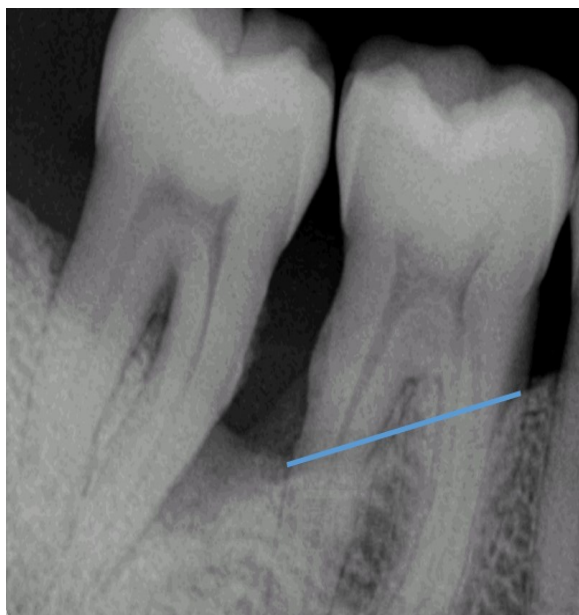Before



After



Case A: Before and after grafting. 0 weeks and 3 months follow up. Prof. Casp Nardy.

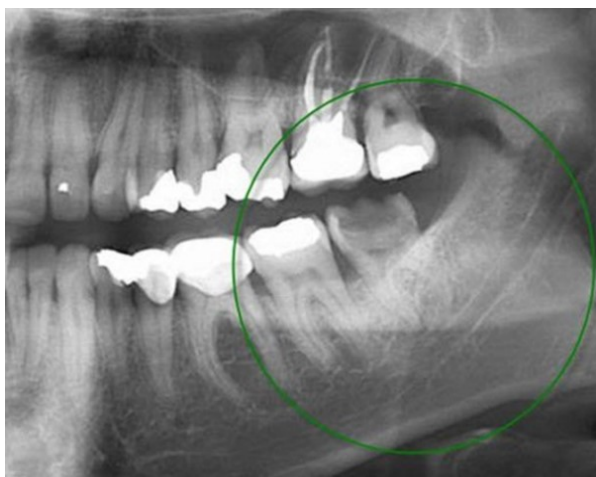

Case B: Before and after grafting. 0 weeks and 1 month follow up. Dr. Cifuni.

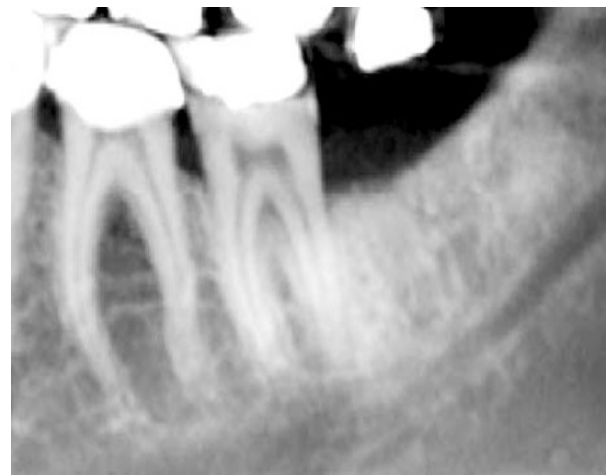Grafting for socket preservation

Case description: Male, 34 years old. Extraction of the tooth #38 and immediate grafting with autologous dentin prepared from roots.

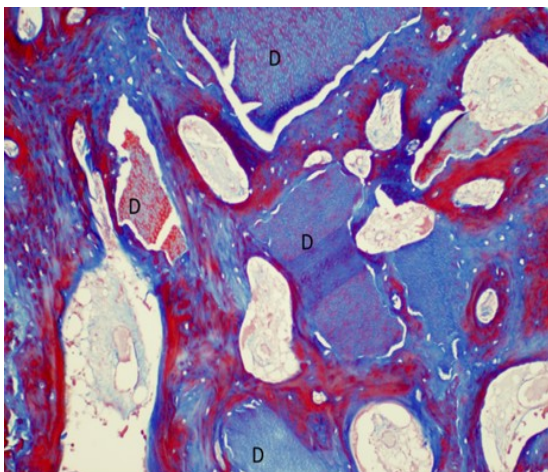
Results: Bone-dentin ankylosed tissue is formed from autologous graft of dentin root particulate. High stability of bone ridge.



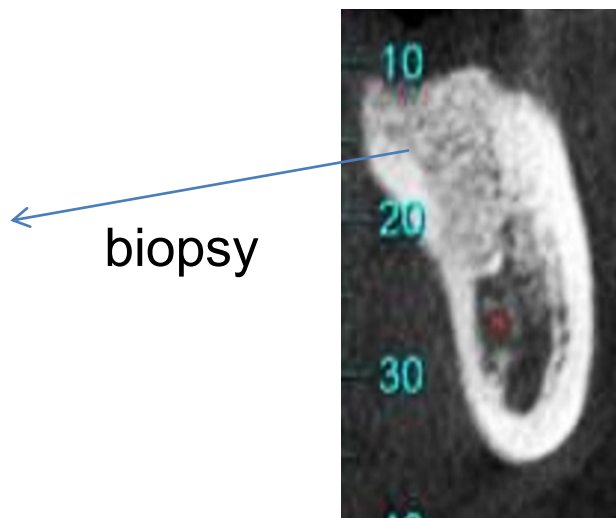
Before extraction



After extraction and grafting



CT imaging of Dentin bone interface



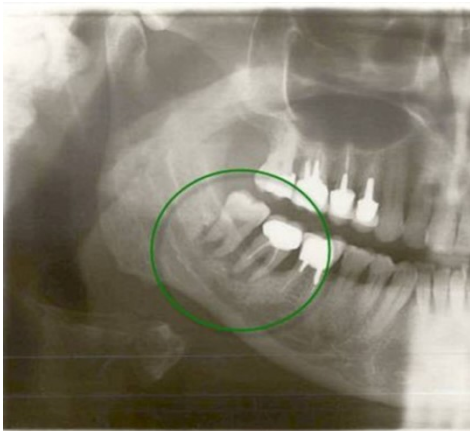
One year after grafting

Dentin grafting and implant prosthodontics

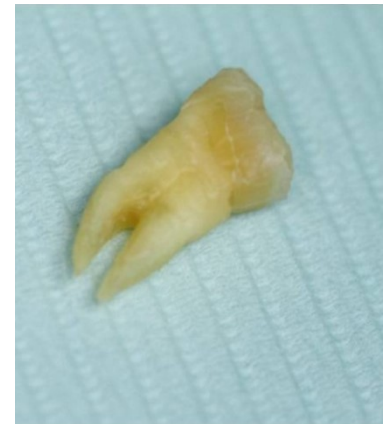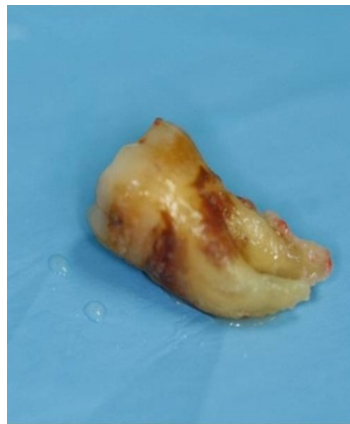
Case description: Male, 56y old, teeth #47;48 advanced periodontitis, mobility and pain.

Treatment: Extraction of teeth #47;48. Tooth #47 discarded because of existing root canal filling. Autologous dentin particles from tooth #48 were prepared and immediately grafted to fill sockets of both teeth and augmentation of site.

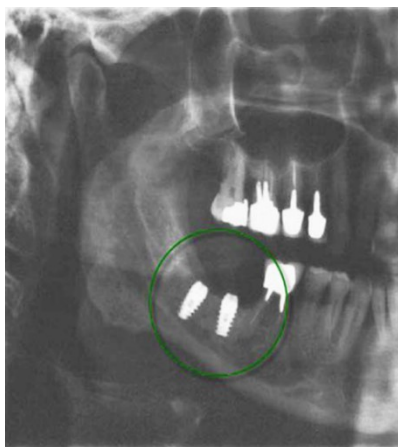
Results: Very strong bone-dentin was formed. Two month after grafting the site was solid. Implants were inserted and prosthetic work performed. **A two year follow up shows that autologous tooth graft is best for long lasting implant stability.**



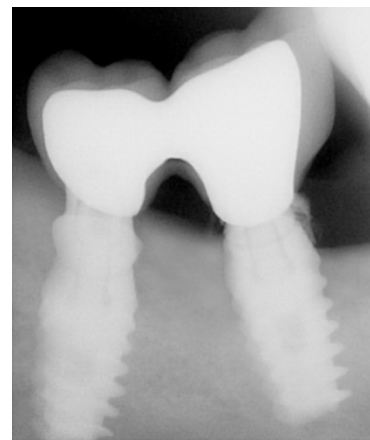
Prior to treatment



Use tungsten carbide burr to reduce all debris from tooth (2-4 minutes).



Implant after 2 months

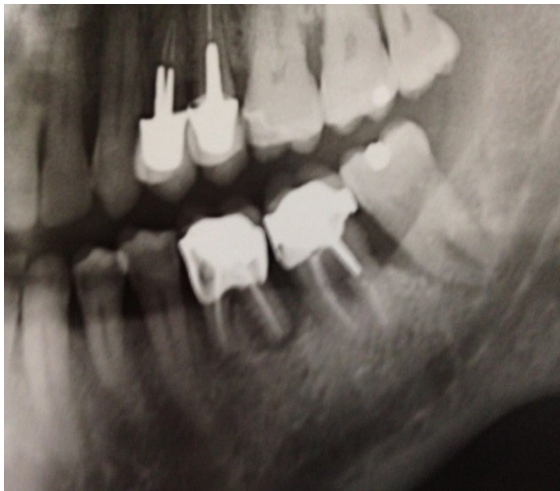

Follow up 2 years after grafting

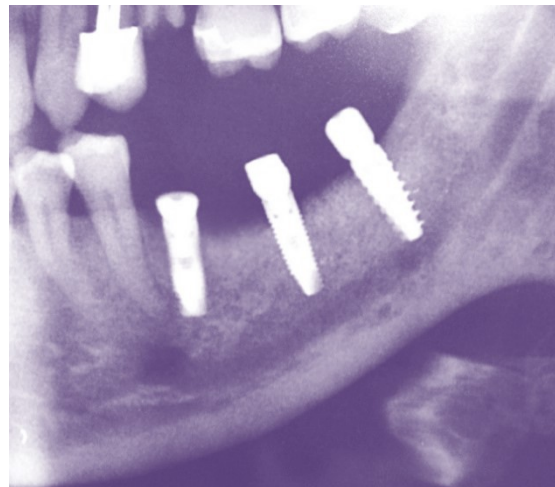
Advanced periodontal disease

Case description: same patient M56, left side of mandible. Here three teeth were extracted #36,37 and 38. Only one tooth was ground and grafted immediately into defect.

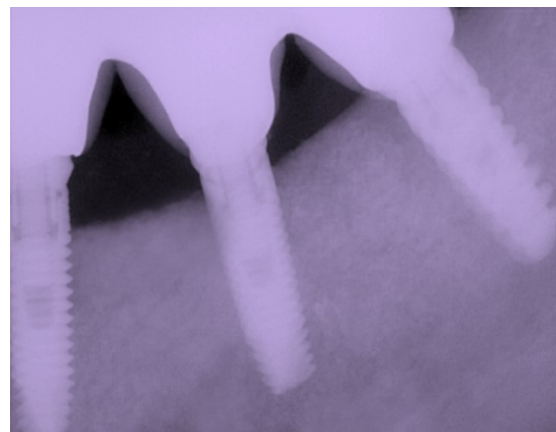
Results: After two month implant stability is achieved. Prosthetic device was accomplished following healing of implant procedure. **A one year follow up shows that autologous tooth graft is best for long lasting implant stability.**



Prior to treatment



2 month after grafting implant insertion.

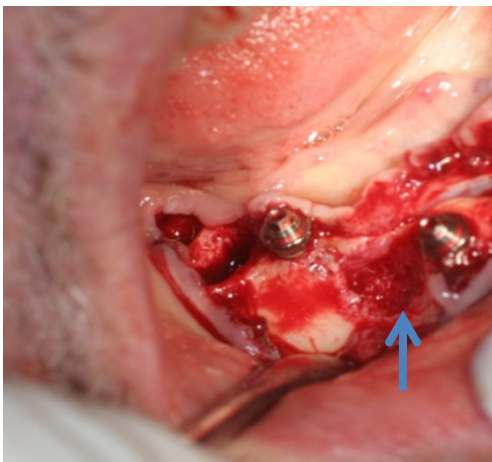


One year follow up

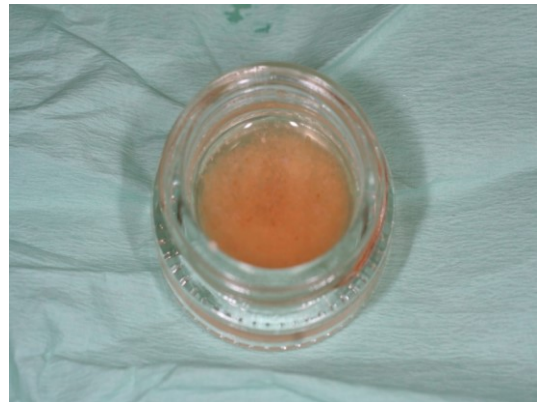Advanced perio case for grafting and implants – dentin graft and minerOSS comparison (part 1)

Case description: Full restoration of mandible with 7 implants where dentin graft was used on the right side and MinerOSS was used on the left side. Extraction sites grafted with Autologous Dentin, in the right side while MinerOSS on the left side of mandible. Implants were placed in between extractions site into the crest. A day later a cast temporary reconstruction was placed on implants. PRF membrane was used on both sides.

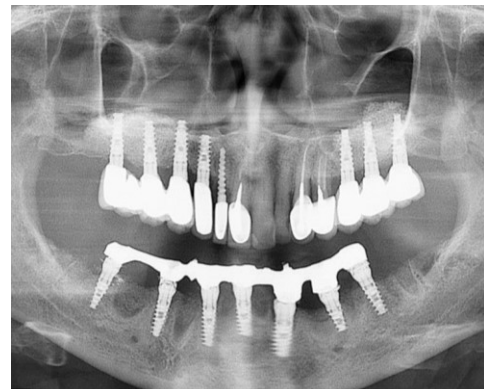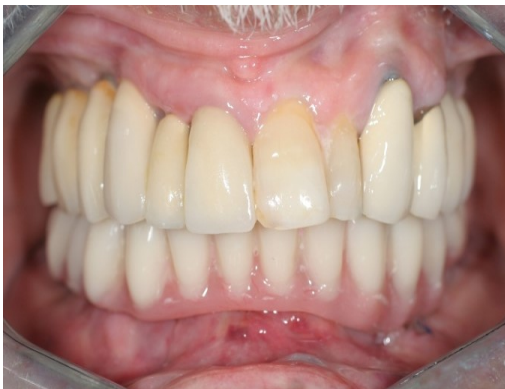Results: Predictable aesthetic results for full mandible restoration based on autologous dentin grafting. **Dentin graft leverages ankylosis which makes it possible to fast pace the restoration and achieve long term aesthetic effect.**



Dentin graft



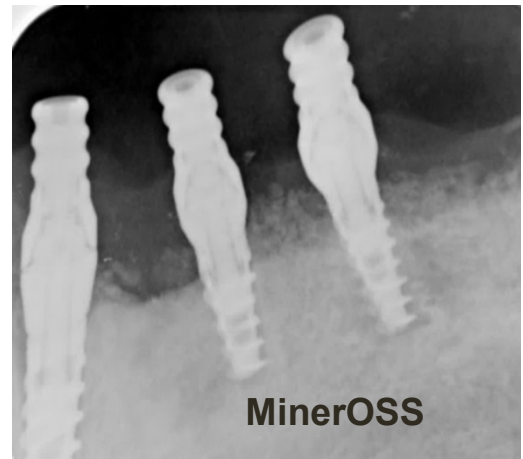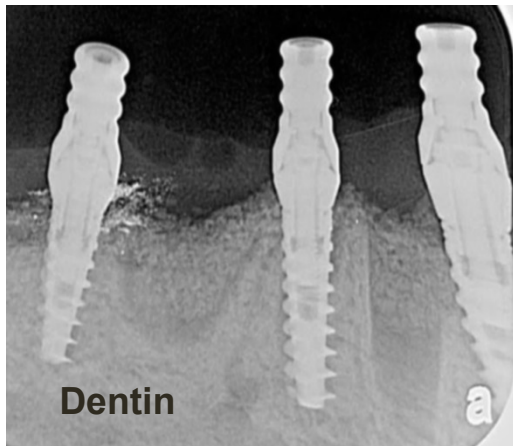
PRF with dentin graft



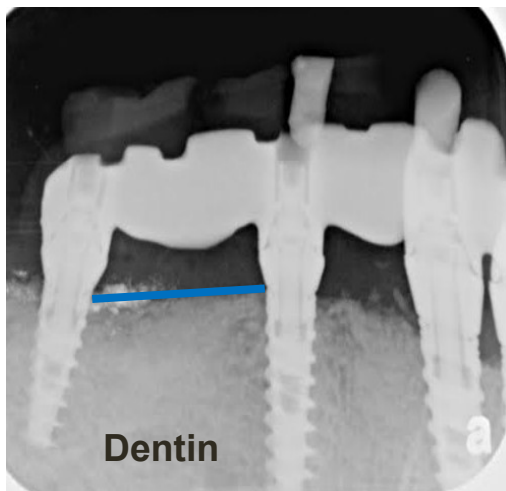
24 hours post grafting and implant insertion a temporary prosthesis was prepared

Advanced perio case for grafting and implants – dentin graft and minerOSS comparison (part 2)

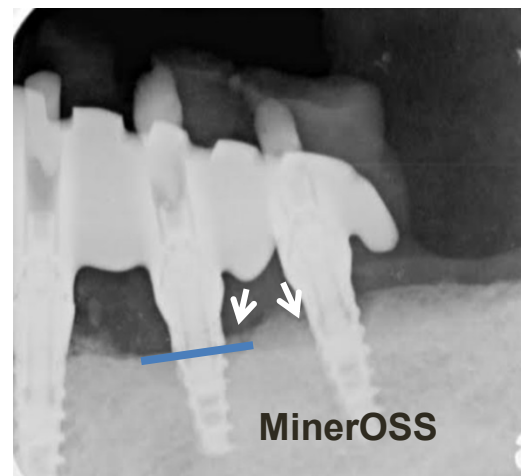
Extraction sites grafted with Autologous Dentin in the right side while MinerOss on the left side of the mandible. Ridge level and bone density was compared across the two grafting options after 18 months.



On day of grafting



Blue line represents bone level. Arrows represent areas of resorption

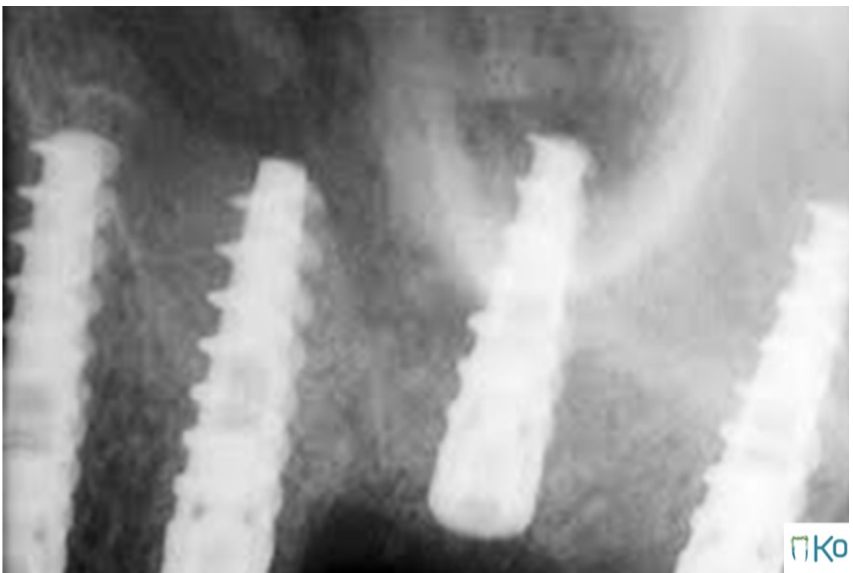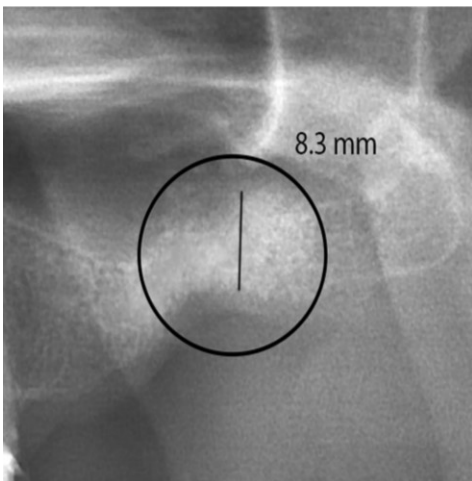
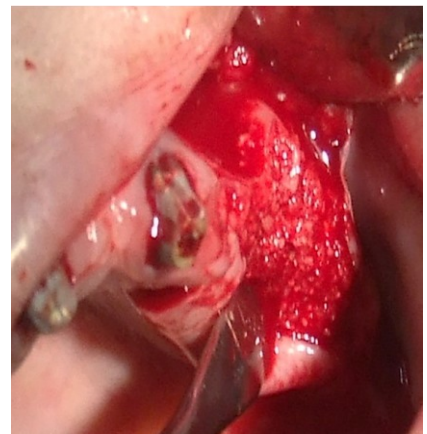

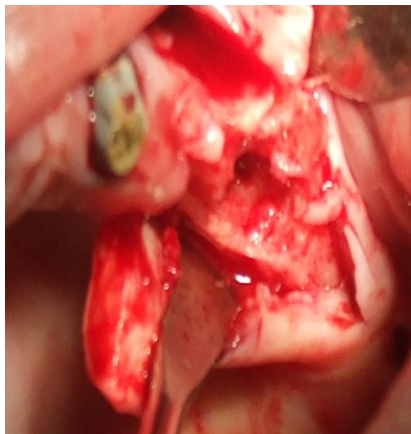
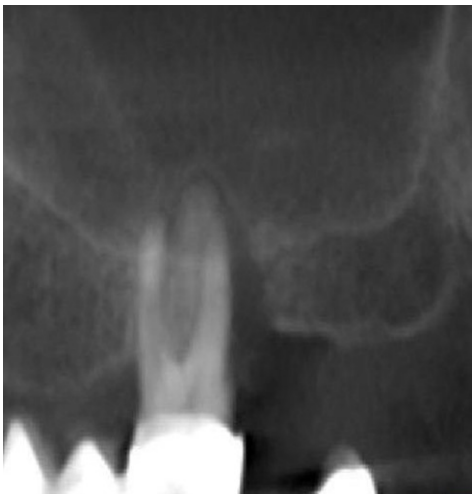18 months after grafting Dentin graft preserved bone level and density while the MinerOSS side presented resorption and bone level reduction

Grafting the sinus (Sinus Lifting)

Case description: Chronic periodontitis and endo-perio involvement of tooth #26. Extraction of tooth #26 exposed the sinus to the root canal (rupture of Schneiderian membrane). The tooth dentin particles were grafted through the roots into the sinus and ridge was augmented. The soft tissue was well sutured using a PRF membrane.

Results: Two month after grafting, bone height of 8.3 mm was achieved at its lowest point. Four implants were placed at this stage. **In conclusion, the affinity of osteogenic cells to autologous dentin made it possible to insert implants 3 month after closed sinus grafting.**



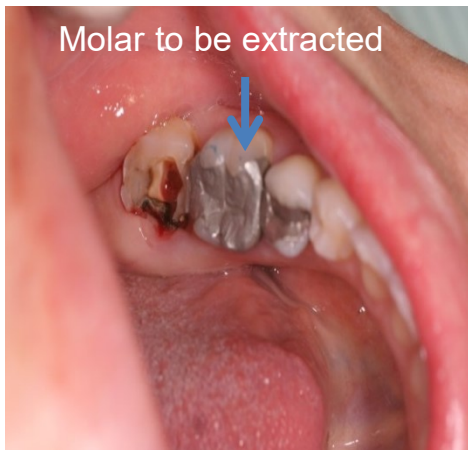Two months after grafting

Three months after grafting

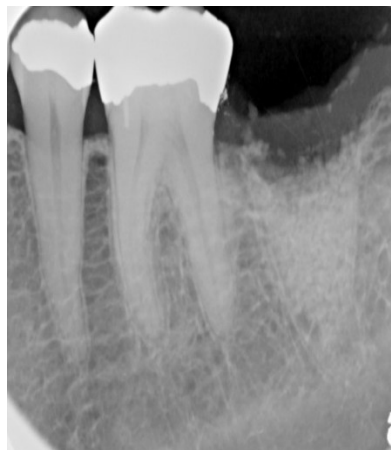Stability of single tooth implant after autologous dentin grafting

Case description: Tooth #36 was extracted because of perforated root . The socket was grafted and during 5 month a permanent restoration on implant was accomplished.

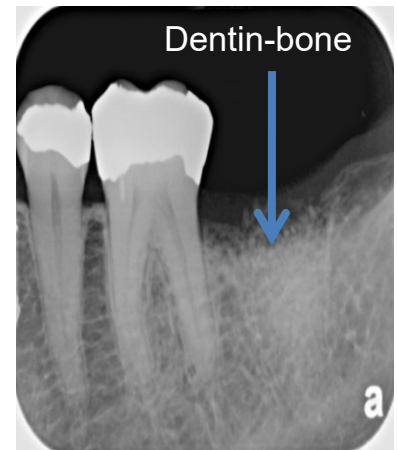
Result: Autologous dentin graft allows shorter healing period and high stability of implant.



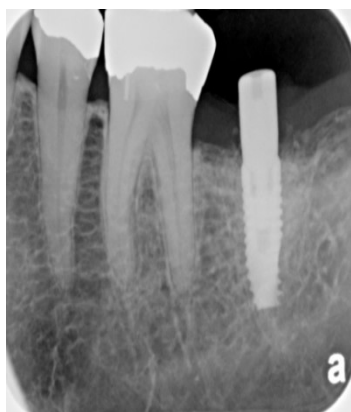
October 2013



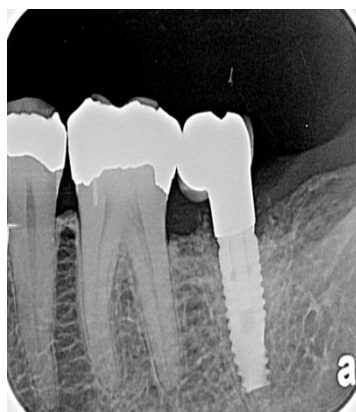*October 2013 –
extraction and graft*



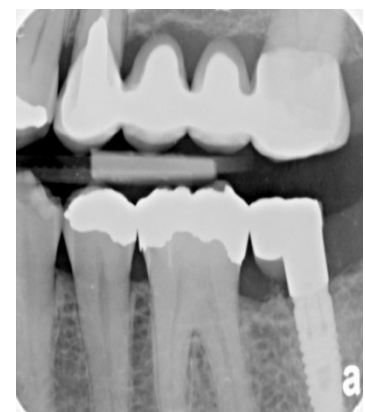*December 2013 –
implant placement*



January 2014



March 2014

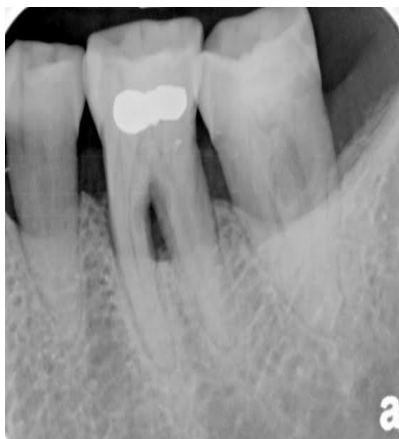

July 2015

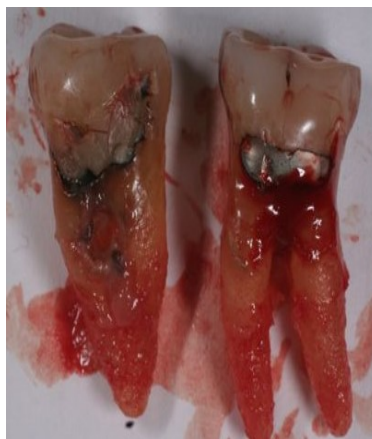Dentin grafting, implant placement and prosthetic restoration in 5 month

Case description: Tooth #36 and #37 were extracted because of periodontal involvement and bone loss. The sockets were grafted and during 5 month a permanent restoration on implants was accomplished.

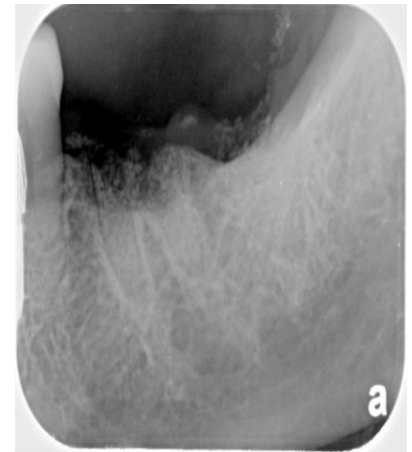
Result: Autologous dentin graft allows shorter healing period, augmentation of the ridge and high stability of implant.



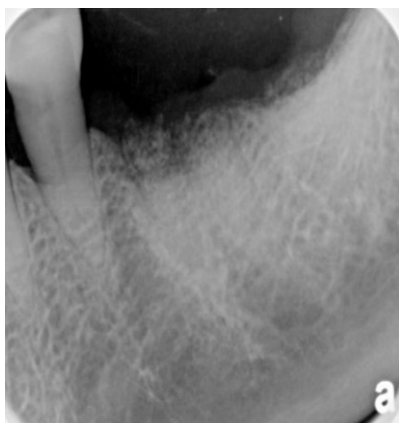
December 2014



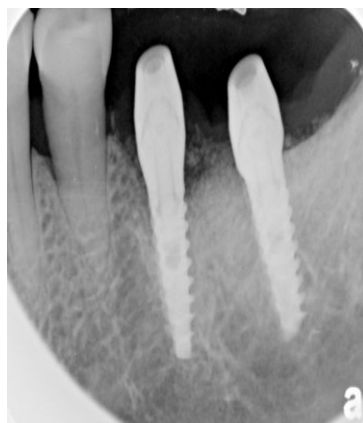Extraction – Dec. 2014



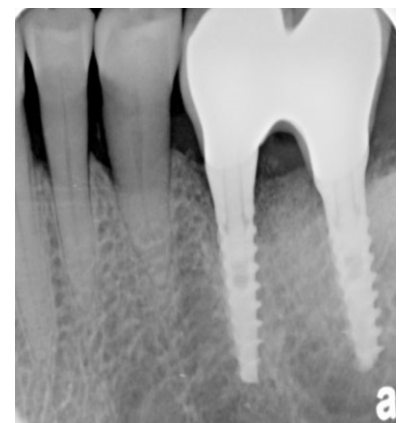
Dentin Grafting – Dec. 2014



Grafted site – Feb. 2015



February 2015



April 2015

Dr. Gideon Hallel DMD MPA

Scientific References

A Novel Procedure to Process Extracted Teeth for Immediate Grafting of Autogenous Dentin. – I. Binderman, G. Hallel, L. Sapoznikov; Interdisciplinary Medicine and Dental Science; 2014

Tissue Engineering of Bone: Critical Evaluation of Scaffold Selection. Itzhak Binderman, Avinoam Yaffe, Yuval Samuni, Hila Bahar, Joseph Choukroun and Philippe Russe; 1Department of Oral Biology, Maurice and Gabriela Goldschleger, School of Dental Medicine, Sackler Faculty of Medicine, Tel Aviv University

Processed Allogenic Dentine as A Scaffold for Bone Healing: An in vivo study; 1 Dr. AL-Namnam, N.M., 1 Shanmuhasuntharam, P., ; AIBAS; 2010

Healing Mechanism and Clinical Application of Autogenous Tooth Bone Graft Material ; Intech; chapter 16; 2013

Human Dentin as Novel Biomaterial for Bone Regeneration ; Masaru Murata¹, Toshiyuki Akazawa²; Interchopen – Biomaterials – Physics and Chemistry; 2011

A New Method for Alveolar Bone Repair Using Extracted Teeth for the Graft Material; Tomoki Nampo,* Junichi Watahiki; J. of Periodontol; 2010

Evaluation of Osteoconductive and Osteogenic Potential of a Dentin Based Bone Substitute Using a Calvarial Defect Model; Ibrahim Hussain, Keyvan Moharamzadeh; Int. J. of Dentistry; 2012

Bone Engineering Using Human Demineralized Dentin Matrix and Recombinant Human BMP-2; University of Hokkaido; Masaru Murata 1757 Kanazawa Tobetsu

Bone Graft Material Using Teeth; Young-Kyun Kim; Seoul National University Bundang Hospital, Seongnam, Korea; 2012

Clinical application of auto-tooth bone graft material; Seoul National University Bundang Hospital, Seongnam, Korea; 2012

Autograft of Dentin Materials for Bone Regeneration; Masaru Murata¹, Toshiyuki Akazawa²; ; Intech;

Development of a novel bone grafting material using autogenous teeth; *ORAL AND MAXILLOFACIAL SURGERY*; 2010

New bone formation around xenogenic dentin grafts to rabbit tibia marrow; Al-Asfour A, Andersson L.; *Dent Traumatol* 2013 Dec; 29(6):455-60.

Dentin xenografts to experimental bone defects in rabbit tibia are ankylosed and undergo osseous replacement; Andersson L.; *Dent Traumatol* 2010 Oct;26(5):398-402.

A prospective study on the effectiveness of newly developed autogenous tooth bone graft material for sinus bone graft procedure; Sang-Ho Jun, Jin-Soo Ahn, Jae-II Lee, Kyo-Jin Ahn, Pil-Young Yun, Young-Kyun Kim; *Journal of Advanced Prosthodont* 2014;6:528-38

Autogenous teeth used for bone grafting: a comparison with traditional grafting materials; Young Kyun Kim, DDS, PhD, Su-Gwan Kim, DDS, PhD, Pil-Young Yun, DDS, PhD.; Seoul National University, Chosun University, and Kangwon National University;

Analysis of Organic Components and Osteoinductivity in Autogenous Tooth Bone Graft Material; Young-Kyun Kim, Junho Lee, Kyung-Wook Kim, In-Woong Um, Masaru Murata, Katsutoshi Ito; Department of Oral and Maxillofacial Surgery, Section of Dentistry, Seoul National University Bundang Hospital, Korea Tooth Bank, R&D Institute, Department of Oral and Maxillofacial Surgery, College of Dentistry, Dankook University, Department of Oral and Maxillofacial Surgery, Health Sciences University of Hokkaido

Coagulation of blood plasma of guinea pig by the bone matrix. Huggins, CB., & Reddi, AH. (1973). *Proc Natl Acad Sci U S A.*, 70., 3., 929-33.

Regenerative Medicine of Bone and Teeth. Kawakami, T., Kuboki, Y., Tanaka, J., Hijikata, S., Akazawa, T., Murata, M., Fujisawa, R., Takita, H., & Arisue, M. (2007). *Journal of Hard Tissue Biology*, 16(3),95-113.

Development of a novel bone grafting material using autogenous teeth. Kim, YK., Kim, SG., Byeon, JH., Lee, HJ., Um, IU., Lim, SC., & Kim, SY. (2010). *Oral Surg Oral Med Oral Pathol Oral Radiol Endod.*, 109., 4., 496-503.

Extracted tooth roots used for lateral alveolar ridge augmentation: a proof-of – concept study. Schwarz F, Golubovic V, Becker K, Mihatovic I. Extracted tooth roots used for lateral alveolar ridge augmentation: a proof-of-concept study. *J Clinical Periodontol* 2016; 43: 345–353. doi: 10.1111/jcpe.12481; Department of Oral Surgery, University atsklinikum Deusseldorf, Deusseldorf, Germany;

Frequently Asked Questions

Can dentin be used as a graft?

Absolutely. Dentin is very similar to bone as for its chemical and biological composition. Furthermore, due to its strength it acts as the ultimate scaffold.

Is Dentin graft better than allograft?

Yes. It is better than allograft due to its autologous nature, same proteins, and no immunogenic response. It is also denser than allograft. Being osteogenic it rapidly differentiates into bone. As a result the site will heal a lot quicker and be ready for restoration at half the time in comparison to allograft. Most importantly it promotes new bone regeneration at the site. You will experience very little graft resorption if any.

Why would I spend 8 minutes making Dentin graft when I can immediately use allograft?

It's a shame to discard perfectly reusable patient's tissue and use artificial bone or cadaver bone when instead the tooth itself can be used in order to provide superior care, extraordinary bone formation and superior soft tissue response.

Sterility of the graft – how do I sterilize the graft?

Our cleanser is very effective in eliminating bacteria and any organic matter. Coupled with the fact that the Dentin graft is autologous, the risk of infection is almost zero and certainly lower than other pre-packaged grafts.

Can I use an autoclave to sterilize the graft?

Yes.

Graft remodeling – how fast does the Dentin Graft remodel and replaced by bone?

Dentin does not resorb but rather it is fused (ankylosed) by bone. Together the fused bone-dentin matrix will remodel very slowly which will maintain the superior aesthetics of the restoration for much longer.

What is the cleanser?

The cleanser is a Sodium Hydroxide solution mixed in 20% ethanol.

Can the graft be stored? For how long?

The Dentin mineralized graft prepared by the Smart Dentin Grinder can be stored at room temperature indefinitely.

Do I grind the entire tooth? Crown, root, pulp, enamel and all?

Yes. You will grind the entire tooth after removing any amalgam or composite during the mechanical cleaning stage.

Why can't I use endodontically treated teeth?

Yes. As long as you know the history of the tooth, the type of materials that were used and are able to remove the GP and any other endo material prior to processing the tooth in the Smart Dentin Grinder. It is not recommended if the tooth is small.

Can I use the Dentin Graft with PRF, blood, membranes and other grafts?

Absolutely. We have documented some great cases using the above. Furthermore, we recommend that you use the Dentin graft the same way that you use any other graft. We are not asking the dentist to change anything in the way they use bone grafts.

Is this FDA approved?

Yes. The product is FDA registered. It is classified as a Type 1 medical device and it is 510K exempt under FDA ruling. Manufacturing is conducted in medical grade (GMP) facilities and all consumable components undergo rigorous sterilization and inspection prior to shipping.

What is the particulate size?

Particle size of 250-1200 microns is produced in the top collection tray and particles smaller than 250 microns are collected in the lower tray. Both size categories can be utilized.

How much graft can I get from a single tooth?

You will get three times the volume of the tooth, t Typically 1cc from an incisor and about 3 CC's from a molar or premolar.

How much research do you have to support this concept?

Our research spans over the last 7 years and includes both scientific studies as well as clinical studies. There is a lot more research that spans across 3 decades. You can access some of the research on our website under the tab Education – www.kometabio.com

What if the tooth has amalgam, composites or deep decay?

All these elements need to be stripped off the tooth by mechanically cleaning the tooth with a tungsten bur prior to placing the tooth in the grinder. The dentist should try and get as much of it off the extracted tooth as possible. As for decay or organic elements, there's no need to eliminate it entirely. If there remain traces of decay and such – these will all be dissolved by the cleanser.

To what extent do I need to mechanically clean the tooth?

Please refer to the previous question. It is important to thoroughly dry the tooth before placing it in the chamber.

Can I use the disposable chamber for more than one tooth?

Yes. As long as the teeth come from the same patient during the same visit. You can't use the same chamber to grind teeth of different people. Doing so will render the graft non-autologous. Please keep in mind that the grinding chamber can't be re-used nor sterilized. The chamber should be discarded after use for a specific patient.

How long do I need to wait after placing the graft before I can place implants or load implants?

Do not change your best practices at first, but your experience will show you that with the Dentin graft you will be getting strong bone formation in about half the time of any other graft.